

A CASE OF BILIARY STONES AND ANASTOMOTIC BILIARY STRICTURE AFTER LIVER TRANSPLANT:

All in One Session



Mario Traina



Marta Di Pisa

Department of Endoscopy,
Istituto Mediterraneo Trapianti e
Terapie ad Alta Specializzazione (IsMeTT)

Introduction

Biliary complications after liver transplant are a very common and relevant problem¹ (8–50%). Untreated biliary complications are associated with a high rate of morbidity and mortality. Magnetic resonance is an effective technique in the evaluation of biliary complications², but endoscopic retrograde cholangiopancreatography (ERCP) and percutaneous transhepatic cholangiography (PTC) remain the gold standard for the therapeutic options (with successful results between 70 and 80%)^{3,4,5}. Common biliary complications after liver transplant are leaks and strictures, which are divided into anastomotic and non-anastomotic. Other less frequent complications include stones, cuts and oddities^{6,7}.

We report a case of biliary anastomotic stenosis and biliary stones after orthotopic liver transplant (OLT) treated with a combined percutaneous radiologic and endoscopic approach (rendezvous technique) and with the use of an electrokinetic lithotripter and Fusion system.

Case report

A 67-year-old male underwent OLT with a choledocho – choledocho anastomosis, because of HCV related cirrhosis, in 2000. The transplant was complicated by renal failure, solved with hemodialysis for one month, but no vascular abnormalities were noted from the Doppler ultrasound examination. Five years later, recurrence of HCV occurred. The patient was treated with antiviral therapy without success, and upon endoscopic evaluation there was evidence of medium-sized esophageal varices. Other co-morbid conditions include severe obesity, hypertension and previous partial gastrectomy for ulcer. He was admitted because of reassessment of the liver disease and occurrence of cholestasis with several episodes of cholangitis.

At the admission, physical examination showed severe obesity (> 30), and no signs of hydro - saline retention. Laboratory data were the following: AST/ALT 130/187 U/L (normal: 5-40/65 U/L), bilirubin tot/dir 26.46/19.69 mg/dl (0-1.5 mg/dL), alkaline phosphates 357 U/L (40-134 U/L), gamma – GT 1161 mg/l. A magnetic resonance cholangiography was not performed because of the severe obesity; ERCP was planned under general anesthesia. The bile duct was cannulated, showing a mild anastomotic stricture with a very tight angle. Above the anastomotic stricture, there were multiple stones, and at the confluence, mild intrahepatic biliary dilation was noted (Fig. 1). A guide wire was passed through the stenosis, but because of the stones and the very tight angle of the

stricture, it was impossible to pass a Dormia basket, Fogarty extraction balloon or any other catheter. Due to these challenges, the ERCP was unsuccessful and a PTC was planned and a 6.6 Fr external - internal biliary catheter was successfully placed (Fig. 2).

In the following days, because of worsening jaundice (bilirubin tot/dir 34.22/28.78 mg/dl), a combined radiologic and endoscopic technique (rendezvous technique) was performed. In the angiographic suite and under general anesthesia, the patient was monitored continuously with electrocardiography, pulse oximeter and automatic recording of blood pressure and pulse. Intravenous antibiotic prophylaxis was performed before the procedure. After visualizing the biliary tree, under fluoroscopic control, using an Amplatz guide wire to gain access, the previously placed biliary drain was changed with a 7 Fr vascular introducer.

With electrokinetic lithotripsy, a ballistic lithotripter which uses high-energy magnetic fields, placed through the introducer, percutaneous lithotripsy was performed; then the sphincterotomy was done (Fusion Pre-loaded OMNI-Tome 21, FS-OMNI-21-480, Cook Endoscopy, Winston Salem, USA). An endoscopic balloon dilatation of the anastomotic stricture was performed using an 8 mm balloon catheter (Fusion Biliary Dilatation balloon, FS-BDB-8x3, Cook Endoscopy, Winston Salem, USA) and, at the same time, under endoscopic control, the stones were completely removed with a Fogarty balloon (Fusion Extraction balloon, FS-8.5-12-15A, Cook Endoscopy, Winston Salem, USA) (Fig. 3). A final cholangiogram showed no filling defects or any stricture and, at the end of the procedure, an external – internal biliary drain (12 Fr) was placed. Two months after the procedure, the patient currently has a biliary catheter in place, is asymptomatic, in good general condition and without signs of cholestasis.

Discussion

Biliary complications after liver transplant are common and biliary stones represent a small part of these ^{1,2}. In the majority of cases, ERCP alone is the best diagnostic and therapeutic treatment with a successful result in 70 – 80% ^{3,4,5} and is a less invasive procedure, although it has some important complications ⁸. Western studies show the efficacy of percutaneous transhepatic choledochoscopy (PTHC) and holmium:yttrium-aluminum-garnet (YAG) laser to remove biliary stones in patients unable or unwilling to undergo endoscopic or surgical removal, but this technique requires many sessions time and prolonged biliary access ⁹.

In our patient, endoscopic management was attempted as a first option but was unsuccessful in placing a stent in the correct position and then removing the stones because of the stenosis and the stones just above the stenosis. Also, PTC was able to place an external – internal biliary catheter but failed to remove the stones and solve the stenosis.

So, we thought to apply the combined radiologic and endoscopic procedure (rendezvous technique), using the Fusion System, associated with the use of a ballistic lithotripter, to solve the problem. In this way, just in one session, we were able to remove the stones and solve the stenosis; also, we tried to avoid surgery for this patient because of three main reasons: severe obesity, presence of a cirrhotic graft and previous surgery for gastric ulcer.

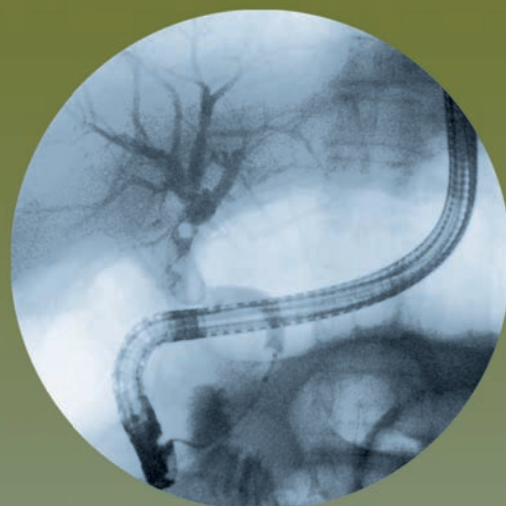


Figure 1

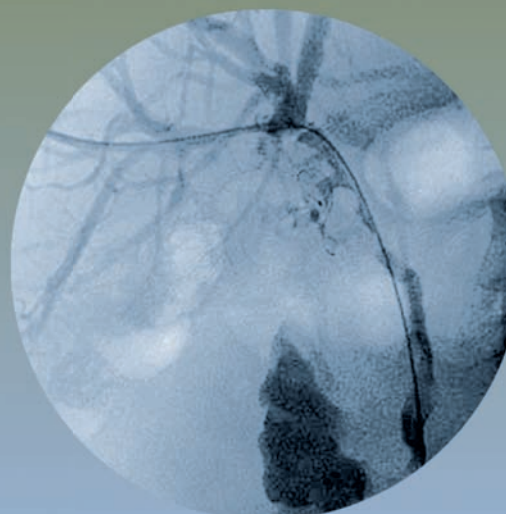


Figure 2

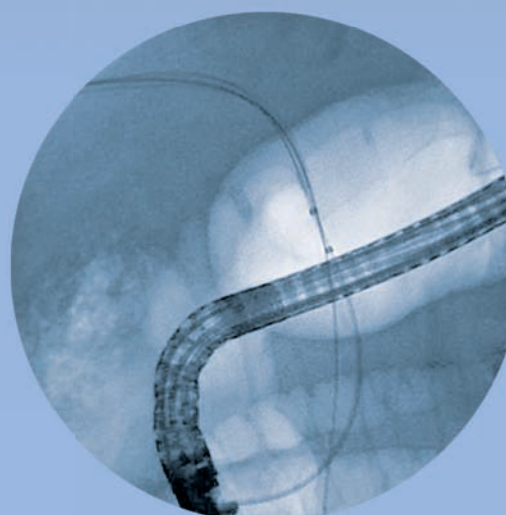


Figure 3

ALL JUST IN ONE SESSION
Continued on page 6

ALL JUST IN ONE SESSION

Continued from page 5

The rendezvous technique has been described in the treatment of benign or malignant biliary obstruction, in traumatic bile duct injury repair and in the treatment of large biliary leak in a liver transplant recipient^{10, 11} but, to our knowledge, this is the first report about the use of this technique in treatment of biliary stones and anastomotic stenosis post liver transplant, associated to a ballistic lithotripter.

In conclusion, rendezvous technique, associated with an electrokinetic lithotripter and the Fusion System, allowed us to use all advanced techniques and devices in one session which required less time. This technique is a feasible alternative for stone removal and biliary stricture management, when prior endoscopic or PTC attempts of removal of stones and stenting the biliary tree have failed. As a result, this approach avoided a possible surgery that could have a higher risk of complications for this kind of patient.

REFERENCES

- 1) Stratta RJ, Wood Rp, Langnas AN et al. Diagnosis and treatment of biliary tract complication after orthotopic liver transplantation. *Surgery* 1989; 106: 675-683
- 2) Boraschi P, Braccini G, Gignoni R, et al. Detection of biliary complications after orthotopic liver transplantation with MR cholangiography. *Magn. Reson. Imaging* 2001; 19: 1097-1105
- 3) Greif F, Bronsther OL, Van Thiel DH et al. The incidence, timing, and management of biliary tract complication after orthotopic liver transplantation. *Ann. Surg* 1994; 219: 40-45.
- 4) Pfau PR, Kochman MI, Lewis JD, et al. Endoscopic management of postoperative complication in orthotopic liver transplantation. *Gastrointestinal Endoscopy* 2000; 52: 55-65.
- 5) Thulavath PJ, Atassi T, Lee J, An endoscopic approach to biliary complications following orthotopic liver transplantation. *Liver Int.* 2003; 23: 156-162.
- 6) Ernst O, Sergent G, Mizrhai D et al. (1999) Biliary leaks: treatment by means of percutaneous transhepatic biliary drainage. *Radiology* 211:345-348
- 7) Pasher A, Neuhaus P, Bile duct complication after liver transplantation. *Transplant International* 2005; 18: 627-642
- 8) Loperfido S, Angelini G, Benedetti G, et al. Major early complications from diagnostic and therapeutic ERCP: a prospective multicenter study. *Gastrointest Endosc* 1998; 48: 1 – 10
- 9) Hazey JW, McCreary M, Guy G, Melvin WS. Efficacy of percutaneous treatment of biliary tract calculi using the holmium:YAG laser. *Surg Endosc.* 2007 Jul;21(7):1180-3.
- 10) Aytakin C, Boyvat F, Yilmaz U et al. (2006) Use of the rendezvous technique in the treatment of anastomotic distruption in a liver transplant recipient. *Liver Transpl* 12:1423-1426
- 11) Usefulness of the "rendezvous" technique in living related right liver donors with post-operative biliary leakage from bile duct anastomosis. R. Miraglia; M. Traina; L. Maruzzelli; S. Caruso; M. Di Pisa; S. Gruttadauria; A. Luca; B. Gridelli. *Cardiovascular and Interventional Radiology* 2008 (in press).